




The Open Urology & Nephrology Journal

Content list available at: <https://openurologyandnephrologyjournal.com>



RESEARCH ARTICLE

M-Type Phospholipase A2 Receptor Staining in Children with Idiopathic Membranous Nephropathy: PLA2R Staining in Children with IMN

Yosuke Inaguma¹, Atsutoshi Shiratori¹, Taku Nakagawa¹, Kyoko Kanda¹, Makiko Yoshida², Shigeo Hara³, Hiroshi Kaito^{1,4}, Kandai Nozu⁴, Kazumoto Iijima⁴, Norishige Yoshikawa⁵ and Ryojiro Tanaka^{1,*}

¹Department of Nephrology, Hyogo Prefectural Kobe Children's Hospital, 1-6-7 Minatojima-minamimachi, Chuo-ku, Kobe, Hyogo 650-0047, Japan

²Department of Diagnostic Pathology, Hyogo Prefectural Kobe Children's Hospital, 1-6-7 Minatojima-minamimachi, Chuoku, Kobe, Hyogo 650-0047, Japan

³Department of Diagnostic Pathology, Kobe City Medical Center General Hospital, 2-1-1 Minatojima-minamimachi, Chuo-ku, Kobe, Hyogo 650-0047, Japan

⁴Department of Pediatrics, Kobe University Graduate School of Medicine, 7-5-2 kusunokicho, Chuo-ku, Kobe, Hyogo 650-0017, Japan

⁵Clinical Research Center, Wakayama Medical University, 811-1 Kimiidera, Wakayama City, Wakayama 641-8509, Japan

Abstract:

Background:

Membranous Nephropathy (MN) is a common cause of nephrotic syndrome in adults that can also occur in children, albeit less frequently. Recently, the M-type phospholipase A2 receptor (PLA2R) was identified as the target antigen in idiopathic membranous nephropathy (IMN), making it a useful marker for diagnosis. However, there are few studies describing the potential role of PLA2R in children with IMN. The aim of this study was to clarify the involvement of PLA2R in childhood IMN.

Methods:

We enrolled 11 patients diagnosed with IMN from January 1998 to March 2017. We performed PLA2R staining in paraffin-embedded renal biopsy sections. The clinical data were collected from the patients' medical records.

Results:

The median age at biopsy was 6 years (range, 4 to 14 years). A single 6-year-old boy among all pediatric patients with IMN had granular PLA2R staining along his glomerular capillary loops and the prevalence of PLA2R-positivity was 9%. He also showed IgG4 co-dominant staining in terms of IgG subclass. There were no apparent differences in his clinical features such as clinical data at the time of renal biopsy, the time from the treatment initiation to remission, and relapse or renal dysfunction during the follow-up period.

Conclusion:

We suggest that PLA2R staining can be a diagnostic tool for patients with IMN of any age, though pediatric patients with IMN have lower prevalence of PLA2R-positive staining than adult patients.

Keywords: Childhood, Idiopathic membranous nephropathy, IgG subclass, Immunofluorescence staining, Phospholipase A2 receptor, Renal biopsy.

Article History

Received: January 09, 2019

Revised: May 13, 2019

Accepted: May 16, 2019

1. INTRODUCTION

Membranous Nephropathy (MN) is a common cause of immune complex-mediated nephrotic syndrome, which can

develop at any age from infants to the elderly [1]. It is pathologically characterized by subepithelial deposits of immune complex [2]. There are a number of etiologies for these deposits, including autoimmune diseases such as Systemic Lupus Erythematosus (SLE), viral hepatitis, malignancy, and drugs such as penicillamine. If such a cause can be identified, it is termed Secondary Membranous Nephropathy (SMN); if none can be identified, it is termed Idiopathic

* Address correspondence to this author at the Department of Nephrology, Hyogo Prefectural Kobe Children's Hospital, 1-6-7 Minatojima-minamimachi, Chuo-ku, Kobe, Hyogo 650-0047, Japan; Tel: +81789457300; Fax: +81783021023; Email: tanaka_kch@hp.pref.hyogo.jp

Membranous Nephropathy (IMN). In adults, IMN needs to be considered during diagnosis, but SMN due to SLE, hepatitis B viral infection, and congenital syphilis is more frequent in children [3]. To decide on the optimal treatment strategy, it is essential to distinguish IMN from SMN.

A recent study showed that a specific antigen called M-type phospholipase A2 receptor (PLA2R) is found on the podocytes of adult patients with IMN [4]. In later studies, it was reported that the sensitivity of the presence of PLA2R autoantibodies in the serum was 70-82%, and the sensitivity of PLA2R staining in glomerular tissue was 74% [4, 5], and it has been shown to be a useful marker for diagnosis of IMN. However, several of these reports only investigated adult patients with IMN.

IMN is a rare disease in children; the International Study for Kidney Disease in Children reported that the incidence of MN was 1.5% in children with nephrotic syndrome [6], and another report showed that 4.5% of the patients who underwent renal biopsy to evaluate proteinuria were diagnosed with MN, with IMN patients constituting 26.4% of all MN patients [7]. There are also few studies on the potential role of PLA2R in childhood IMN [8 - 10]. Therefore, to clarify the involvement of PLA2R in childhood IMN, we performed immunofluorescent staining using an anti-PLA2R antibody in renal biopsy specimens of Japanese pediatric patients with IMN.

2. MATERIALS AND METHODS

2.1. Patients

The present study enrolled 11 patients whose diagnosis of IMN was pathologically made from kidney biopsies at Hyogo Prefectural Kobe Children's Hospital and Kobe University Hospital from January 1998 to March 2017. Patients were excluded if they had possible causes of SMN such as autoimmune diseases, hepatitis B or C viral infection and malignancy. The following data were collected from the patients' medical records: age, gender, serum creatinine (Cr), serum albumin, urine Protein to Creatinine Ratio (uPCR), hematuria at the time of the renal biopsy, the period from onset to the renal biopsy, treatment, and the period from treatment initiation to remission. Glomerular Filtration Rate (GFR) was estimated using serum Cr according to the new Schwartz formula [11]. The treatment strategy was formulated at the discretion of the attending physician. The results of light and electron microscopy, and immunofluorescent staining in all patients were reviewed.

2.2. Pathological Evaluation

All renal biopsy specimens were fixed in formalin and embedded in paraffin. All paraffin sections were stained with hematoxylin and eosin, periodic acid-Schiff, Masson trichrome, and periodic acid-methenamine-silver. The visual findings caused by deposition of immune complexes, such as subepithelial deposits, spike formation, and thickening or bubbling of the glomerular capillary loops, were evaluated using light and electron microscopy. All direct immunofluorescence specimens using frozen sections were stained with

fluorescein-tagged rabbit polyclonal antibodies to immunoglobulin G (IgG), IgA, IgM, complement component 1q (C1q), C3, and C4. Additionally, IgG subclass analysis for paraffin-embedded or frozen sections was performed using antibodies against IgG1, IgG2, IgG3, and IgG4 (Invitrogen, Camarillo, CA, USA), followed by fluorescein isothiocyanate-conjugated secondary antibodies (Invitrogen) [12]. The paraffin-embedded and frozen sections were used for IgG subclass analysis of patients 1-7 and patients 8-11, respectively. The paraffin-embedded sections were deparaffinized, and proteinase K was applied for 30 min at room temperature. Each staining intensity was evaluated on a five-grade scale of 0-3+ (0, negative; <1+, spare; 1+, weak; 2+, moderate; 3+, strong). IMN was divided into segmental IMN and global IMN on the basis of the lesion occupied by the IgG deposits along the glomerular capillary on immunofluorescence. Segmental IMN was defined as a lesion occupying less than 50% of the glomerulus, and global IMN comprised a lesion occupying more than 50%. The cases of IMN were staged using electron microscopy images according to the Ehrenreich and Churg classification [13].

2.3. PLA2R Immunofluorescence

PLA2R was detected in formalin-fixed, paraffin-embedded renal biopsy sections using rabbit polyclonal anti-PLA2R1 antibodies (Sigma-Aldrich, St. Louis, MO, USA) at a dilution of 1:50 followed by highly cross-adsorbed Alexa Fluor 488 goat anti-rabbit IgG (Life Technologies, Carlsbad, CA) at a dilution of 1:100 as previously described [2]. PLA2R staining images were assessed using a conventional immunofluorescence microscope (Olympus, Tokyo, Japan). Each image was run with a positive and negative control. If there was bright granular staining along the glomerular capillary loops for PLA2R, it was considered positive.

2.4. Clinical Outcome

During the follow-up period, remission was defined as resolution of proteinuria and hematuria after treatment. Renal dysfunction was defined as an estimated GFR <90 mL/min/1.73m².

3. RESULTS

The clinical data of the 11 patients who were diagnosed with IMN are shown in Table 1. The median age at the biopsy was 6 years (range, 4 to 14 years), with 7 boys and 4 girls. School urine screening led to the diagnosis of 9 patients, 1 was diagnosed after the appearance of edema, and 1 was diagnosed at pregnancy. Nephrotic syndrome was found at the time of renal biopsy in 3 patients. The average proteinuria at the time of the renal biopsy was 1.9 g/g·Cr, the average serum albumin was 3.2 mg/dL, and serum Cr levels were normal in all patients. As shown in Fig. 1, only patient 8 showed bright granular staining along the glomerular capillary loops for PLA2R, with a positive staining rate of 9%. He was a 6-year-old who was diagnosed incidentally as a result of school urine screening. He had moderate proteinuria (1.9 g/g·Cr), hematuria, as well as mild hypoalbuminemia (3.3 mg/dL) at the time of the renal biopsy.

Table 1. Clinical characteristics of patients diagnosed with idiopathic membranous nephropathy at the time of the renal biopsy.

Patient	Age (Years)	Gender	Serum Creatinine (mg/dL)	eGFR (mL/min/1.73 m ²)	Serum Albumin (mg/dL)	uPCR (g/g·Cr)	Hematuria (RBCs/HPF)
1	4	F	0.25	176.8	2.9	1.5	20 - 29
2	14	F	0.49	134.9	1.2	4.4	1 - 4
3	6	M	0.34	138.5	1.6	1.9	5 - 9
4	4	M	0.3	143.2	4.1	NA	30 - 49
5	6	M	0.4	118.7	3.5	NA	10 - 19
6	5	M	0.33	131.4	2.1	2.5	20 - 29
7	11	M	0.38	144.6	3.9	0.9	0 - 1
8	6	M	0.28	168.2	3	1.9	20 - 29
9	7	F	0.43	124.9	4.4	0.3	10 - 19
10	8	M	0.32	170.4	2.9	1.6	5 - 9
11	11	F	0.34	170.1	2.8	1.8	10 - 19

eGFR: estimated Glomerular Filtration Rate, uPCR: urine Protein to Creatinine Ratio, NA: data not available, RBCs/HPF: Red Blood Cells/High-Powered Fields

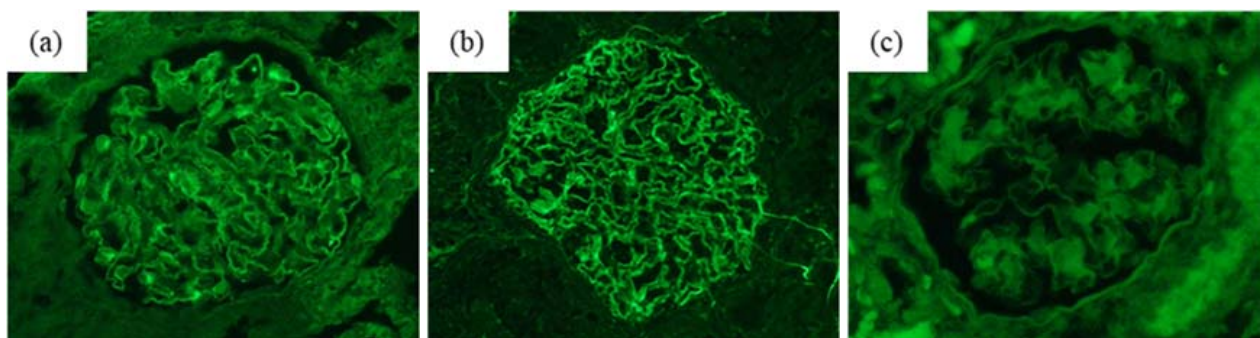


Fig 1. Phospholipase A2 receptor staining pattern in idiopathic membranous nephropathy. (a) Granular staining for phospholipase A2 receptor (PLA2R) along with glomerular capillary loops in a 6-year-old boy. (b) Granular staining for PLA2R along with glomerular capillary loops in a positive control. (c) No staining for PLA2R in the glomerulus of a negative control.

Table 2. Pathological findings including immunofluorescence and electron microscopy findings. staining intensity on five-grade scale of 0 - 3+; 0, negative; <1+, spare; 1+, weak; 2+, moderate; 3+, strong

Patient	Immunofluorescence											Electron Microscopy	
	PLA2R	IgG	IgA	IgM	C3	C4	C1q	IgG Subclass				Lesions with IgG Deposits	Ehrendreich-Churg stage
								IgG1	IgG2	IgG3	IgG4		
1	-	2+	0	<1+	0	0	0	0	0	1+	0	global	stage 1/2
2	-	1+	1+	0	<1+	1+	0	0	0	0	0	global	stage 1
3	-	3+	<1+	1+	1+	<1+	1+	0	0	2+	1+	global	stage 1
4	-	2+	0	0	<1+	0	0	0	0	0	0	NA	stage 1
5	-	2+	0	1+	2+	0	0	0	0	2+	0	NA	stage 1/2
6	-	2+	0	0	0	0	1+	0	0	1+	0	segmental	stage 2
7	-	2+	0	0	<1+	0	0	0	0	1+	0	global	stage 1
8	+	2+	0	0	1+	0	0	1+	0	<1+	1+	global	stage 1
9	-	2+	1+	0	0	0	2+	0	0	1+	0	segmental	stage 2
10	-	3+	0	0	<1+	3+	0	<1+	0	0	1+	global	stage 2
11	-	3+	1+	0	2	3+	0	1+	1+	0	3+	global	stage 1

PLA2R: Phospholipase A2 receptor, NA: data not available, Ig: Immunoglobulin, C: Complement

The pathological characteristics are shown in Table 2. Immunofluorescence examination showed that all patients had granular deposits of IgG along the glomerular capillary loops,

and 8 patients were positive for C3. IgM and IgA staining were positive in 3 and 4 patients, respectively. C1q staining was positive in 3 patients, one of whom showed a “full house”

pattern. IgG subclass staining was performed in all patients and was positive in 9 patients. IgG4 dominant or co-dominant staining was observed in 3 of the 9 patients, 1 of whom was PLA2R-positive. IgG3 dominance was observed in 6 patients. Electron microscopy showed that all patients had subepithelial deposits of immune complex, a characteristic finding of MN. According to the Ehrenreich and Churg classification, 6 patients were in stage 1, 3 were in stage 2, and 3 were in an intermediate stage between 1 and 2.

The clinical outcomes during the follow-up period are shown in Table 3. During follow-up, 9 of 11 patients were in remission, and 1 patient with PLA2R-positive staining was in remission within 9 months after the initiation of treatment. The remaining 2 patients did not reach remission because the follow-up period was less than 12 months after the initiation of treatment, but proteinuria and hematuria decreased in both patients. They are currently being treated. None of the 9 patients who had remission relapsed or suffered from renal dysfunction. None of the patients had any indication of SMN clinically and serologically during the follow-up.

4. DISCUSSION

The measurement of serum anti-PLA2R antibody and PLA2R staining of glomerular tissue have been previously reported as useful diagnostic markers of IMN in adults. Phospholipase A2(PLA2), the ligand of PLA2R, plays a key role in inositol-related biological pathway [14]. Physiological significance of PLA2 in MN is not clear, but studies on various diseases has been advanced [15]. Some studies reported that some patients with MN may not have detectable anti-PLA2R antibodies in their serum but have PLA2R deposition in their glomerular capillary loops. Thus, immunofluorescence for PLA2R staining is equivalent or more sensitive than serological measurements for the diagnosis of IMN [16, 17]. In children, the incidence of IMN is lower than in adults, and there are few reports on the involvement of PLA2R in childhood IMN. Therefore, we performed immunofluorescent staining using anti-PLA2R antibodies in renal biopsy specimens from pediatric patients with IMN, and investigated the involvement of PLA2R in childhood IMN.

The most remarkable finding in our study was that even younger patient with IMN showed positive staining of PLA2R.

Some previous reports indicated that all PLA2R-positive pediatric patients with IMN were older than 10 years, suggesting that PLA2R might play a role in adolescent and preteen IMN patients [8, 9]. Combined with the single previous report [10], IMN patients at any age could be PLA2R-positive in kidney specimens. Further accumulation of data is required to confirm our findings.

In our study, one patient showed bright granular staining along the glomerular capillary loops for PLA2R and the prevalence of PLA2R-positivity was 9%. The prevalence of PLA2R staining along glomerular capillary loops in adult patients with IMN has been reported to range between 53% and 84% [5, 18 - 20]. In children, Cossey *et al.* reported that PLA2R-positivity was found in 45% of IMN patients [8]. On the other hand, Kanda *et al.* reported that it was only observed in 6% of pediatric patients with IMN in Japan [9], which was almost equivalent to our findings. There may be several explanations for this discrepancy; first, the differences in the prevalence of PLA2R staining may be due to the studies' small sample sizes. Second, it may also be explained by differences in the racial makeup of the study cohorts in the USA and Japan. In adult IMN patients, the prevalence of anti-PLA2R antibodies was 70-82% in American patients [4, 5, 19], whereas that in Japanese was only 50-55% [18, 20, 21]. A clear mechanism linking PLA2R-positivity with race is unknown. Third, differences in the prevalence of PLA2R-positivity may be related to age; the median age of the study patients reported by Cossey *et al.* was 14 years [8], whereas in our study it was 6 years. Finally, the different prevalence may also be related to disease activity and the degree of proteinuria. Beck and Salant speculated that the absence of anti-PLA2R antibodies in the serum indicated an absence of immunologic disease activity at the time [22]. In addition, Qin *et al.* reported that in patients who had achieved remission, PLA2R antigen deposits showed a trend towards decrease or remaining unchanged, whereas in patients not in remission, they tended to increase or remained stable [17].

We performed IgG subclass analysis with immunofluorescence staining for all renal biopsy specimens in our study. The previous studies had suggested that IgG4 dominant staining was associated with IMN, whereas SMN was dominantly stained with IgG1, IgG2 and IgG3 [18, 23]. On

Table 3. Clinical outcome during follow-up.

Patient	The Period from Onset to Renal Biopsy (months)	Treatment	The period from Treatment Initiation to Remission (months)	Renal Dysfunction	Follow-up After Treatment Initiation (months)
1	3	ACE-I	5	-	66
2	1	PSL	2	-	37
3	NA	PSL, ACE-I, ARB	16	-	75
4	2	PSL	19	-	106
5	1	PSL	8	-	138
6	1	PSL	5	-	50
7	2	ACE-I	13	-	40
8	2	ACE-I	9	-	33
9	9	ACE-I	5	-	11
10	7	ACE-I	no remission	-	7

(Table 3) contd....

Patient	The Period from Onset to Renal Biopsy (months)	Treatment	The period from Treatment Initiation to Remission (months)	Renal Dysfunction	Follow-up After Treatment Initiation (months)
11	3	ACE-I	no remission	-	11

PSL: prednisolone, ACE-I: angiotensin converting enzyme inhibitor, ARB: angiotensin II receptor blocker, NA: data not available

the other hand, IMN with segmentally positive staining of IgG, which is called segmental IMN, showed different pattern of IgG subclass staining; positive staining of IgG1 and IgG3 [23]. These would result from the difference of stage in IMN, which means that segmental IMN would be thought as either an early stage or incomplete form of global IMN [23]. In our study, 3 patients with global IMN had IgG4 dominant staining and 2 patients with segmental IMN showed IgG3 dominant staining, suggesting that this finding is consistent with a similar trend reported by Segawa *et al.* [23]. In terms of the relation between PLA2R and IgG subclass analysis, the previous report mentioned that serum anti-PLA2R antibody in human consists of IgG4, and the PLA2R antigen could be co-localized with IgG4 in glomerular immune deposits of IMN [4, 24]. IgG4 dominant deposits in glomeruli were mainly found in PLA2R related patients [19]. Consistent with these findings, 1 patient who was PLA2R-positive showed IgG4 co-dominant staining in IgG subclass. IgG subclass analysis, as well as PLA2R staining, would achieve a certain result to confirm IMN in children.

Several limitations exist with respect to this study. First, the sample size of our study was small. Second, we were unable to mention about anti-PLA2R antibodies in the serum which we did not measure. Although PLA2R staining of glomerular tissue is equivalent or more sensitive than serological measurements for the diagnosis of IMN in adults, if we had evaluated serum anti-PLA2R antibodies, it might have been revealed that the serum findings correlate with the renal biopsy findings.

CONCLUSION

In conclusion, this study showed that the IMN patient who was positive for PLA2R was a young boy. Although the prevalence of PLA2R-positivity in pediatric patients with IMN was lower than adult patients, PLA2R staining can be a diagnostic tool for patients with IMN of any age.

ETHICS APPROVAL AND CONSENT TO PARTICIPATE

This study was approved by Ethical Committee of Hyogo Prefectural Kobe Children's Hospital No: 26-20.

HUMAN AND ANIMAL RIGHTS

All procedures performed in this studies involving human participants were in accordance with the ethical standards of the institutional and/or national research committee and with the 1964 Helsinki declaration and its later amendments or comparable ethical standards.

CONSENT FOR PUBLICATION

Inform consent was obtained from all the participants.

AVAILABILITY OF DATA AND MATERIALS

Not applicable.

FUNDING

K. Iijima reports grants from Novartis Pharma K.K., grants from Japan Blood Product Organization, grants from AbbVie LLC, grants from JCR Pharmaceuticals Co., Ltd., grants from Daiichi Sankyo, Co., Ltd., grants from Teijin Pharma Ltd., grants from CSL Behring, grants from Novo Nordisk Pharma Ltd., grants from Air Water Medical Inc., grants from Astellas Pharma Inc., grants from Takeda Pharmaceutical Co., Ltd., grants from Taisho Toyama Pharmaceutical Co., Ltd., grants from Eisai Co. Ltd., grants from Biofermin Pharmaceutical Co., Ltd., from Zenyaku Kogyo Co., personal fees from Zenyaku Kogyo Co., Ltd., personal fees from Novartis Pharma K.K., personal fees from Chugai Pharmaceutical Co., Ltd., personal fees from Astellas Pharma Inc., personal fees from Springer Japan KK, personal fees from Meiji Seika Pharma Co., Ltd., personal fees from Asahi kasei Pharma Corporation, personal fees from Medical Review Co.,Ltd, personal fees from Nippon Boehringer Ingelheim Co., Ltd., personal fees from Baxter Limited, personal fees from Ono Pharmaceutical Co., Ltd., personal fees from Sanwa Kagaku Kenkyusho Co.,Ltd., personal fees from Sanofi K.K., personal fees from Alexion Pharma LLC., personal fees from Kyowa Hakko Kirin Co., Ltd., outside the submitted work.

CONFLICT OF INTEREST

Y. Inaguma, A. Shiratori, T. Nakagawa, K. Kanda, M. Yoshida, S. Hara, H. Kaito, K. Nozu, N. Yoshikawa and R. Tanaka declare that there is no conflict of interest in this study.

ACKNOWLEDGEMENTS

Declared none.

REFERENCES

- [1] Ayalon R, Beck LH Jr. Membranous nephropathy: Not just a disease for adults. *Pediatr Nephrol* 2015; 30(1): 31-9. [<http://dx.doi.org/10.1007/s00467-013-2717-z>] [PMID: 24375012]
- [2] Larsen CP, Messias NC, Silva FG, Messias E, Walker PD. Determination of primary *versus* secondary membranous glomerulopathy utilizing phospholipase A2 receptor staining in renal biopsies. *Mod Pathol* 2013; 26(5): 709-15. [<http://dx.doi.org/10.1038/modpathol.2012.207>] [PMID: 23196797]
- [3] Beck LH Jr. Childhood membranous nephropathy and dietary antigens. *Am J Kidney Dis* 2012; 59(2): 174-6. [<http://dx.doi.org/10.1053/j.ajkd.2011.09.009>] [PMID: 22014402]
- [4] Beck LH Jr, Bonegio RG, Lambeau G, *et al.* M-type phospholipase A2 receptor as target antigen in idiopathic membranous nephropathy. *N Engl J Med* 2009; 361(1): 11-21. [<http://dx.doi.org/10.1056/NEJMoa0810457>] [PMID: 19571279]
- [5] Qin W, Beck LH Jr, Zeng C, *et al.* Anti-phospholipase A2 receptor antibody in membranous nephropathy. *J Am Soc Nephrol* 2011; 22(6): 1137-43. [<http://dx.doi.org/10.1681/ASN.2010090967>] [PMID: 21566055]
- [6] Nephrotic syndrome in children: Prediction of histopathology from clinical and laboratory characteristics at time of diagnosis. A report of the International Study of Kidney Disease in Children. *Kidney Int*

- 1978; 13(2): 159-65.
[<http://dx.doi.org/10.1038/ki.1978.23>] [PMID: 713276]
- [7] Lee BH, Cho HY, Kang HG, *et al.* Idiopathic membranous nephropathy in children. *Pediatr Nephrol* 2006; 21(11): 1707-15.
[<http://dx.doi.org/10.1007/s00467-006-0246-8>] [PMID: 16951933]
- [8] Cossey LN, Walker PD, Larsen CP. Phospholipase A2 receptor staining in pediatric idiopathic membranous glomerulopathy. *Pediatr Nephrol* 2013; 28(12): 2307-11.
[<http://dx.doi.org/10.1007/s00467-013-2574-9>] [PMID: 23903693]
- [9] Kanda S, Horita S, Yanagihara T, Shimizu A, Hattori M. M-type phospholipase A₂ receptor (PLA₂R) glomerular staining in pediatric idiopathic membranous nephropathy. *Pediatr Nephrol* 2017; 32(4): 713-7.
[<http://dx.doi.org/10.1007/s00467-016-3552-9>] [PMID: 27921164]
- [10] Kumar V, Ramachandran R, Kumar A, *et al.* Antibodies to M-type phospholipase A2 receptor in children with idiopathic membranous nephropathy. *Nephrology (Carlton)* 2015; 20(8): 572-5.
[<http://dx.doi.org/10.1111/nep.12478>] [PMID: 26194981]
- [11] Schwartz GJ, Muñoz A, Schneider MF, *et al.* New equations to estimate GFR in children with CKD. *J Am Soc Nephrol* 2009; 20(3): 629-37.
[<http://dx.doi.org/10.1681/ASN.2008030287>] [PMID: 19158356]
- [12] Hara S, Goto S, Kamiura N, *et al.* Reappraisal of PLA2R1 in membranous nephropathy: Immunostaining method influence and association with IgG4-dominant phenotype. *Virchows Arch* 2015; 467(1): 87-94.
[<http://dx.doi.org/10.1007/s00428-015-1754-3>] [PMID: 25820371]
- [13] Ehrenreich T, Porush JG, Chung J, *et al.* Treatment of idiopathic membranous nephropathy. *N Engl J Med* 1976; 295(14): 741-6.
[<http://dx.doi.org/10.1056/NEJM197609302951401>] [PMID: 958260]
- [14] Vitale SG, Rossetti P, Corrado F, *et al.* How to achieve high-quality oocytes? The key role of Myo-Inositol and melatonin. *Int J Endocrinol* 2016; 20164987436
[<http://dx.doi.org/10.1155/2016/4987436>] [PMID: 27651794]
- [15] Laganà AS, Rossetti P, Sapia F, *et al.* Evidence-based and patient-oriented inositol treatment in polycystic ovary syndrome: Changing the perspective of the disease. *Int J Endocrinol Metab* 2017; 15(1)e43695
[<http://dx.doi.org/10.5812/ijem.43695>] [PMID: 28835764]
- [16] Debiec H, Ronco P. PLA2R autoantibodies and PLA2R glomerular deposits in membranous nephropathy. *N Engl J Med* 2011; 364(7): 689-90.
[<http://dx.doi.org/10.1056/NEJMc1011678>] [PMID: 21323563]
- [17] Qin HZ, Zhang MC, Le WB, *et al.* Combined assessment of phospholipase A2 receptor autoantibodies and glomerular deposits in membranous nephropathy. *J Am Soc Nephrol* 2016; 27(10): 3195-203.
[<http://dx.doi.org/10.1681/ASN.2015080953>] [PMID: 26989120]
- [18] Hayashi N, Akiyama S, Okuyama H, *et al.* Clinicopathological characteristics of M-type phospholipase A2 receptor (PLA2R)-related membranous nephropathy in Japanese. *Clin Exp Nephrol* 2015; 19(5): 797-803.
[<http://dx.doi.org/10.1007/s10157-014-1064-0>] [PMID: 25492250]
- [19] Hofstra JM, Beck LH Jr, Beck DM, Wetzels JF, Salant DJ. Anti-phospholipase A₂ receptor antibodies correlate with clinical status in idiopathic membranous nephropathy. *Clin J Am Soc Nephrol* 2011; 6(6): 1286-91.
[<http://dx.doi.org/10.2215/CJN.07210810>] [PMID: 21474589]
- [20] Hihara K, Iyoda M, Tachibana S, *et al.* Anti-phospholipase A2 receptor (PLA2R) antibody and glomerular PLA2R expression in Japanese patients with membranous nephropathy. *PLoS One* 2016; 11(6)e0158154
[<http://dx.doi.org/10.1371/journal.pone.0158154>] [PMID: 27355365]
- [21] Akiyama S, Akiyama M, Imai E, Ozaki T, Matsuo S, Maruyama S. Prevalence of anti-phospholipase A2 receptor antibodies in Japanese patients with membranous nephropathy. *Clin Exp Nephrol* 2015; 19(4): 653-60.
[<http://dx.doi.org/10.1007/s10157-014-1054-2>] [PMID: 25412738]
- [22] Beck LH Jr, Salant DJ. Membranous nephropathy: Recent travels and new roads ahead. *Kidney Int* 2010; 77(9): 765-70.
[<http://dx.doi.org/10.1038/ki.2010.34>] [PMID: 20182413]
- [23] Segawa Y, Hisano S, Matsushita M, *et al.* IgG subclasses and complement pathway in segmental and global membranous nephropathy. *Pediatr Nephrol* 2010; 25(6): 1091-9.
[<http://dx.doi.org/10.1007/s00467-009-1439-8>] [PMID: 20151159]
- [24] Hofstra JM, Debiec H, Short CD, *et al.* Antiphospholipase A2 receptor antibody titer and subclass in idiopathic membranous nephropathy. *J Am Soc Nephrol* 2012; 23(10): 1735-43.
[<http://dx.doi.org/10.1681/ASN.2012030242>] [PMID: 22956816]